

## SAMPLING PHOTOS

Photo 1. Caudal Blood Sample



Photo 2. Foil Covered Teflon Tube

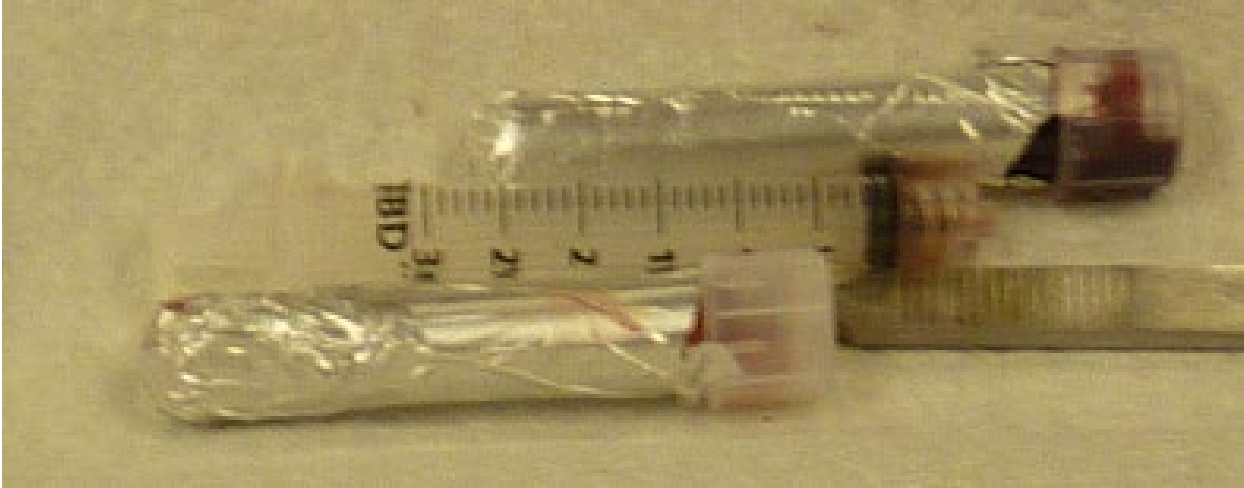

Photo 3. Cardiac Blood Sample

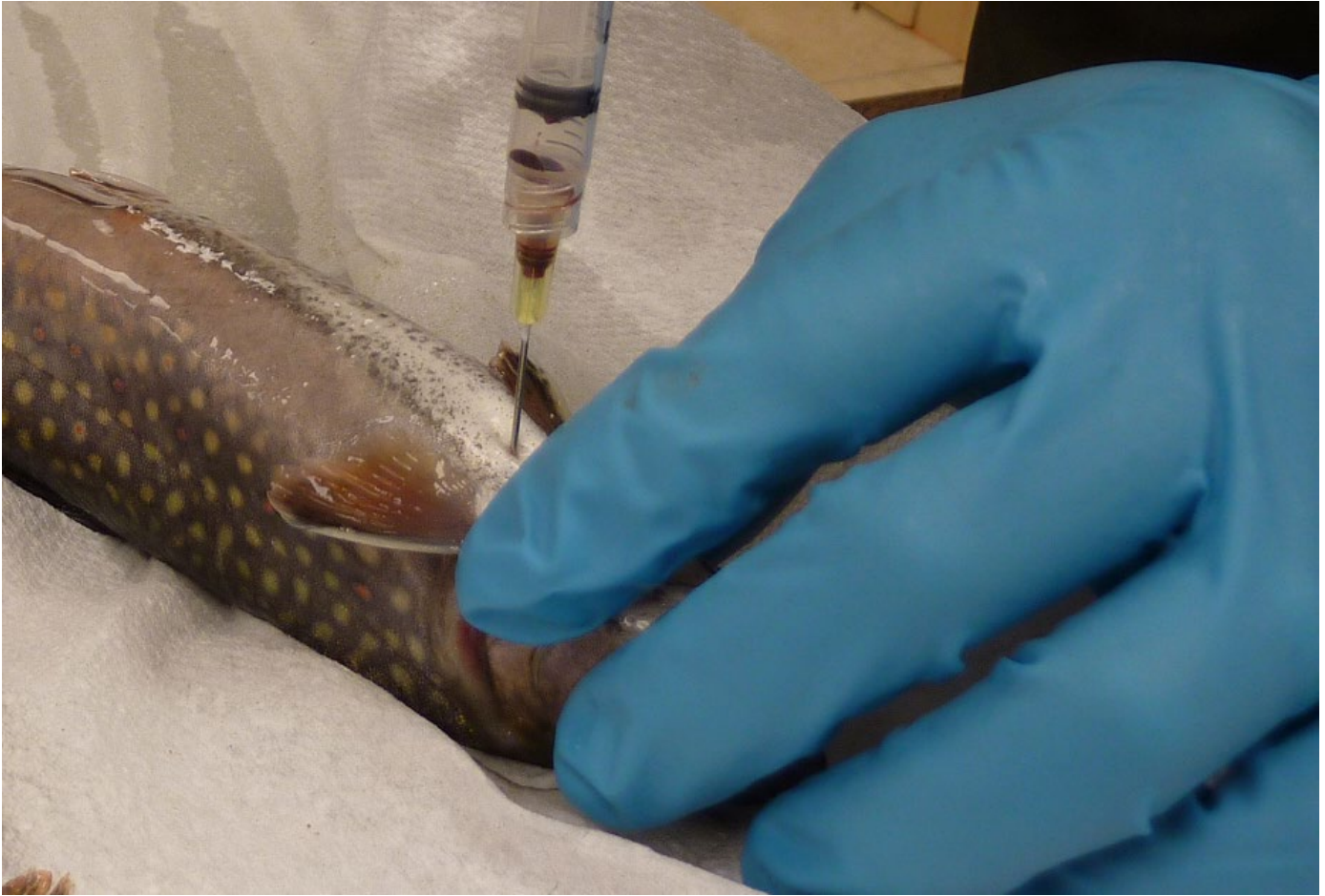
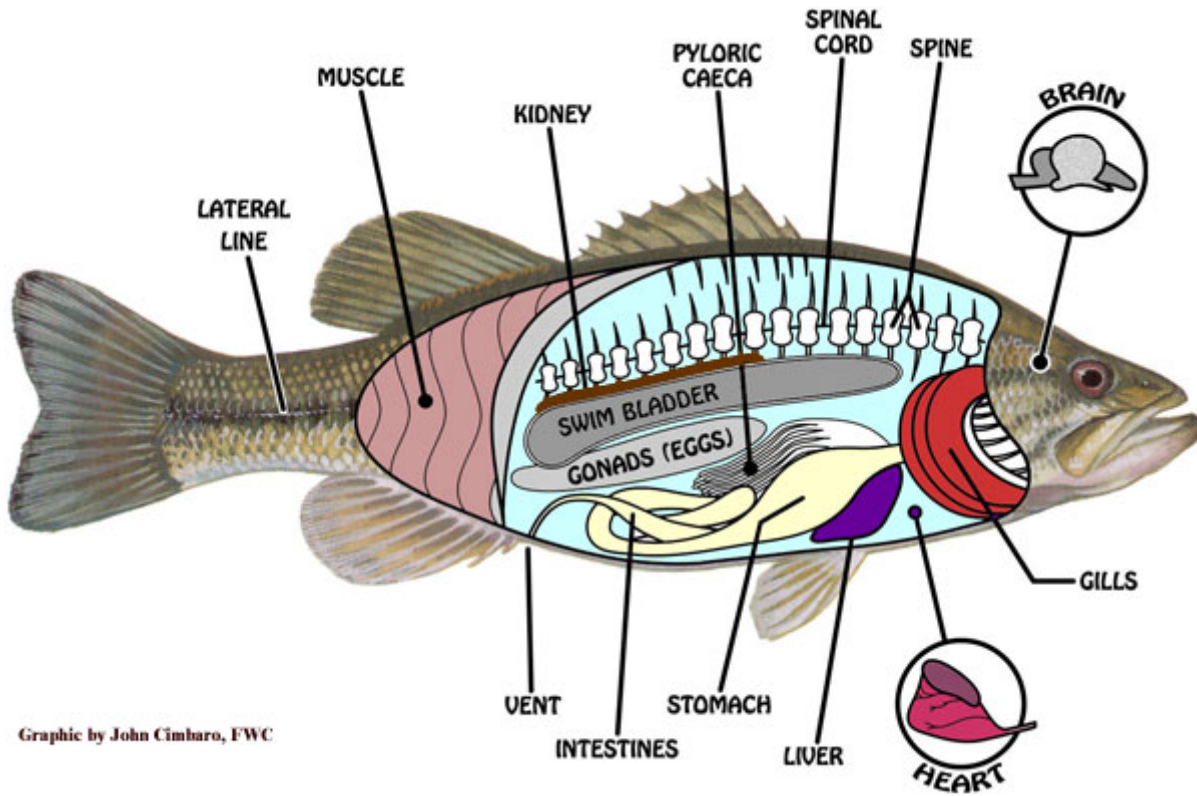


Photo 4. Abdominal Incision

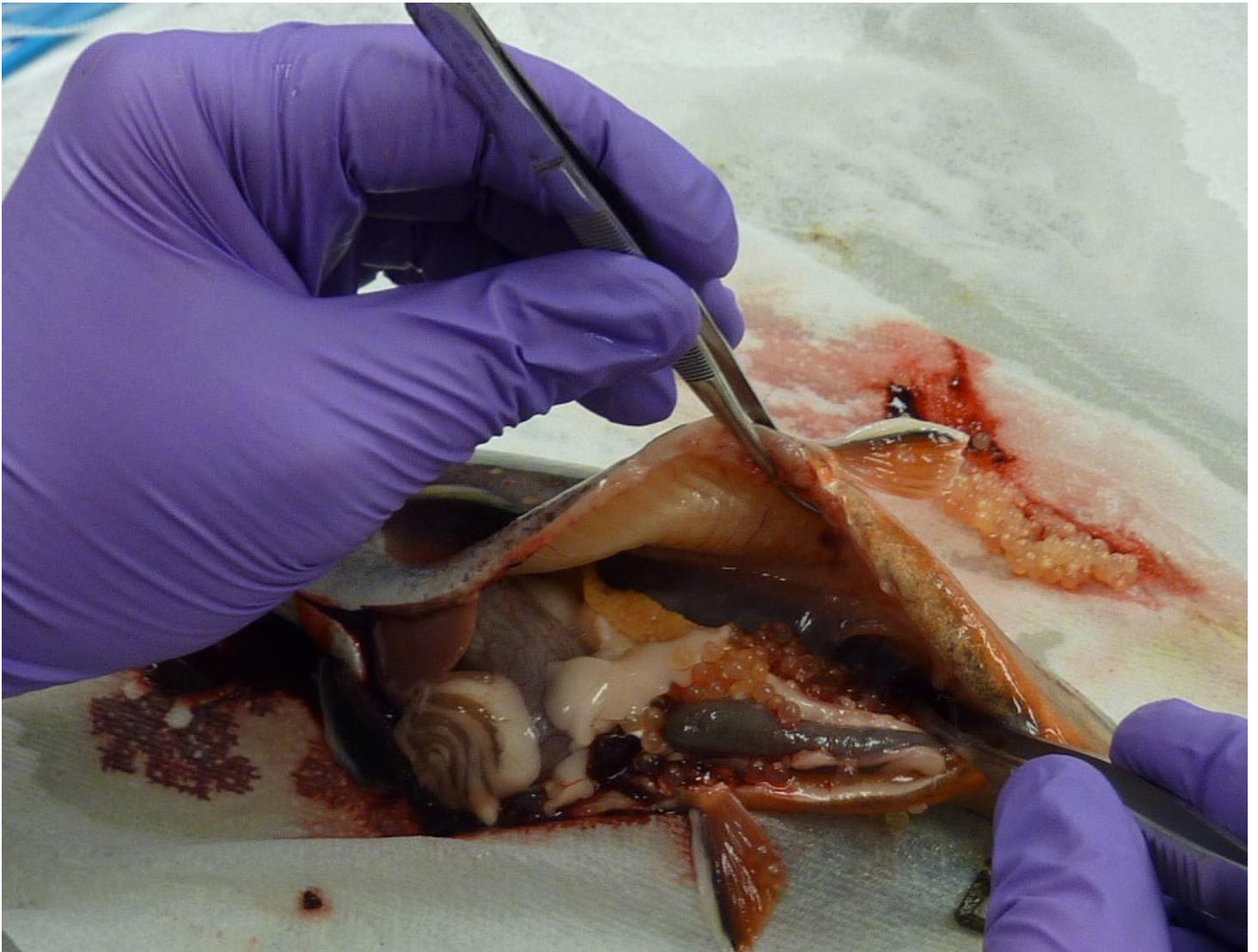



Photo 5. Position of the liver.



Graphic by John Cimbaro, FWC